

CASE REPORT

## MOSAIC INTRACHROMOSOMAL TRIPLICATION OF (12)(p11.2p13) IN A PATIENT WITH PALLISTER-KILLIAN SYNDROME

Yakut S<sup>1</sup>, Mihci E<sup>2</sup>, Altiock Clark O<sup>3</sup>, Cetin Z<sup>1</sup>, Keser I<sup>1</sup>, Berker S<sup>1</sup>, Luleci G<sup>1,\*</sup>

**\*Corresponding Author:** Professor Dr. Guven Luleci, Department of Medical Biology and Genetics, School of Medicine, Akdeniz University, Arapsuyu, Antalya, Turkey; Tel.: +90-242-249-69-70; Fax: + 90-242-227-44-95; E-mail: luleci@akdeniz.edu.tr

### ABSTRACT

Pallister-Killian syndrome (PKS) is a rare genetic disorder usually characterized by mosaic tetrasomy of isochromosome 12p detected in cultured fibroblast cells. We describe here a patient with PKS and intrachromosomal triplication of the short arm of chromosome 12. Her karyotype was mos 46,XX,inv trp(12)(p11.2p13)[34]/46,XX[16] *de novo* by conventional cytogenetics and fluorescent *in situ* hybridization (FISH) analysis. However, this chromosomal abnormality was not detected from the patient's cultured blood lymphocytes. We report here the third patient with intrachromosomal triplication on the short arm of chromosome 12, presenting a PKS phenotype.

**Key words:** Pallister-Killian syndrome (PKS); Tetrasomy 12p; Intrachromosomal triplication.

### INTRODUCTION

Pallister-Killian syndrome (PKS, OMIM #601803) is a rare sporadic disorder caused by mosaicism for tetrasomy of the short arm of chromosome 12 resulting from an supernumerary isochromosome 12p [1,2].

The karyotype in the cultured blood lymphocytes is normal in most cases, but one supernumerary isochromosome 12p is present in high percentage in cultured skin fibroblasts and bone marrow cells of the patients [3]. Supernumerary anaphoid inverted duplicated chromosome 12p and a supernumerary ring chromosome consisting of two copies of chromosome 12p have also been reported in the rare cases with PKS [4,5]. Clinical features of this syndrome include; mental retardation, pigmentary skin abnormalities, seizures, prominent forehead with temporal balding, hypertelorism, short nose, short neck, flat nasal bridge, flat occiput and macrosomia [6,7].

Intrachromosomal triplications leading to partial tetrasomies of the certain chromosome 12 regions have been reported in two patients [8,9]. In this report, we present the third patient who has mosaic intrachromosomal triplication on the short arm of chromosome 12.

### CASE REPORT

A 9-year-old girl was referred to us because of developmental delay and mental retardation. She was the third child of non consanguineous parents. Both parents were 43 years old at the time of the patient's birth. The family history was remarkable because the child of the patient's paternal uncle had severe mental retardation and a supernumerary inverted duplicated marker chromosome derived from chromosome 15. The patient's siblings were clini-

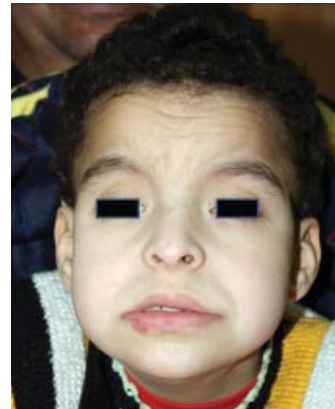<sup>1</sup> Department of Medical Biology and Genetics, School of Medicine, Akdeniz University, Antalya, Turkey

<sup>2</sup> Department of Pediatric Genetics, School of Medicine, Akdeniz University, Antalya, Turkey

<sup>3</sup> Department of Medical Genetics, School of Medicine, Akdeniz University, Antalya, Turkey

cally normal. She was born at term by Cesarean section (birth weight was 6200 gr).

On examination, she could not speak or walk, her weight was 20.5 kg (3-10 percentile) and height was 110 cm (below 3 percentile). She had a prominent forehead, high frontal hair line, low-set ears, sparse eyebrows, hypertelorism, full cheeks, long philtrum, high arched palate, macroglossia, gingival hypertrophy, mandibular prognathism and muscular hypotonia (Figure 1). She also had hypermobile joints and pes equinovarus of the left foot. Cranial computed tomography showed bilateral frontal subdural hygroma (Table 1). Her other system examinations were normal.

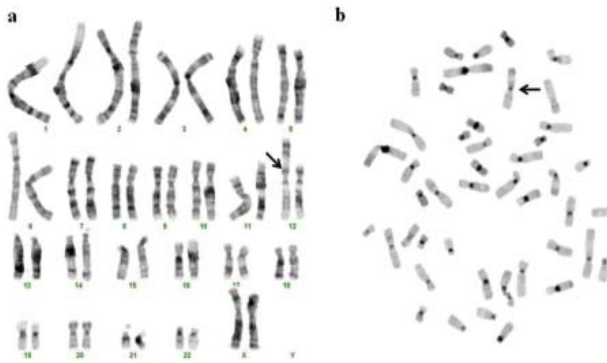


**Figure 1.** Frontal view of the patient's head at 9 months of age.

**Table 1.** Comparison of the patient's clinical findings with a previously reported patient with an intrachromosomal triplication.

Clinical Findings <sup>a</sup>	This Study	[9]
<b>Triplicated segment</b>	trp(12)(p11.2p13)	trp(12)(p11.2p13)
<b>Age at examination</b>	9 years old	at birth
<b>Sex</b>	female	male
<b>Coarse face</b>	[+]	[+]
<b>Mandibular prognathism</b>	[+]	[-]
<b>Thin upper lip</b>	[-]	[+]
<b>Sparse eyebrows</b>	[+]	[-]
<b>Hypertelorism</b>	[+]	[-]
<b>High broad forehead</b>	[+]	[+]
<b>Abnormal ears</b>	[+]	[-]
<b>Epicanthal folds</b>	[-]	[-]
<b>Broad nasal bridge</b>	[-]	[+]
<b>Long philtrum</b>	[+]	[-]
<b>Bitemporal alopecia</b>	[-]	[+]
<b>Macroglossia</b>	[+]	[-]
<b>High arched palate</b>	[+]	[+]
<b>Microcephaly</b>	[-]	[-]
<b>Pigmentation anomalies</b>	[-]	[-]
<b>Terminal hypoplasia of fingers</b>	[-]	[-]
<b>Muscular hypotonia</b>	[+]	[+]
<b>Abnormal fat accumulation</b>	[-]	[-]
<b>Visceral anomalies</b>	[-]	[-]
<b>Anal anomalies</b>	[-]	[-]
<b>Abnormal genitalia</b>	[-]	[-]
<b>Severe mental retardation</b>	[+]	[+]
<b>Hearing loss</b>	[-]	[-]
<b>Macrosomia at birth</b>	[-]	[-]
<b>Other findings</b>	gingival hypertrophy; frontal subdural hygroma; pes equinovarus	single palmar crease

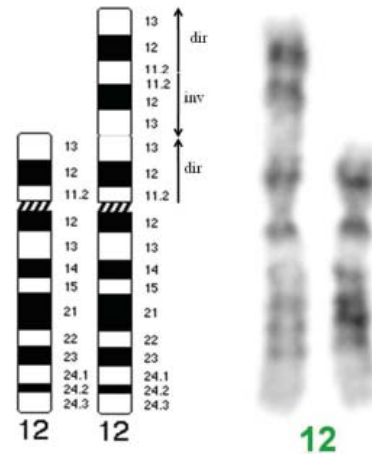
<sup>a</sup> Table is adapted from Huang *et al.* [19].



**Figure 2.** a) The patient's GTG-banded karyotype, b) The patient's CBG- banded metaphase chromosomes.

A short-term phytohemagglutinin-stimulated peripheral blood lymphocyte culture was performed according to a standard procedure [10]. Analysis of 100 of the patient's lymphocyte metaphases by G-bands by trypsin using Giemsa staining showed the karyotype to be 46,XX (Figure 2,3). Skin fibroblasts from the patient were cultured in two different flasks including 2 mL of AmnioGrow (Cytogen GmbH, Bienenweg, Germany) and Chang Medium-D (Irvine Scientific, Santa Ana, CA, USA) at 37°C in a CO<sub>2</sub> incubator and harvested by standard methods [10]. Intrachromosomal triplication of the p11.2p13 region on one chromosome 12 was found in 68% of the metaphases of the skin fibroblasts. C-band by barium hydroxide using Giemsa analysis showed the triplicated chromosome to be monocentric. The parents' lymphocytes showed a normal karyotype.

Fluorescent in situ hybridization (FISH) analysis [11] was performed on metaphase plates from the patient using To TelVysion subtelomeric probe set (Vysis Inc., Downers Grove, IL, USA) according to the manufacturer's instructions. Images were recorded using a Zeiss Axioplan epifluorescence microscope equipped with a CCD camera (Photometrics Sensys, Tucson, AS, USA) and analyzed using MacProbe v4.3 software. The FISH results on 15 metaphases showed two signals for the 12p subtelomeric region on the abnormal chromosome 12 and one on the normal chromosome 12. This analysis confirmed that the tetrasomy 12p arose by an inverted duplication mechanism. The patient's karyotype was designated as mos 46,XX,inv trp(12)(p11.2p13)[34]/46,XX[16]



**Figure 3.** The patient's partial karyotype and an ideogram showing chromosome 12 pair.

according to International System for Human Cytogenetic Nomenclature (ISCN 2009) [12].

## DISCUSSION

Intrachromosomal triplications are rare events and the middle segment usually being inverted in orientation, as in our case [8]. In the majority of cases, triplications were interstitial, whereas there is only one published report of triplication of a whole chromosome arm [9]. In most cases, triplications had originated from maternal chromosomes [13]. Our case is the second patient with intrachromosomal triplication of a whole chromosome arm.

To the best of our knowledge, only two patients with intrachromosomal triplication of the short arm of chromosome 12 have been presented in the literature. In the article by Eckel et al. [8], the 12p11.22-p12.3 region was triplicated and this region does not cover the critical PKS region, which defined the chromosomal region 12pter-p12.3. Therefore, the patient's clinical phenotype was similar to trisomy 12p syndrome rather than the PKS. Unexpectedly, the intrachromosomal triplication was found in all peripheral blood lymphocytes. Also, this intrachromosomal triplication was found in 12% of the mother's peripheral blood lymphocytes. The clinical findings were compatible with the PKS that were reported by Powis et al. [9]. During conventional cytogenetic analyses, triplicated chromosome 12 was observed in 30% of the cultured fibroblasts but not in peripheral blood lymphocytes. However, array-based comparative genomic hybridization analysis showed a triplication of the 12p in the peripheral blood lymphocytes

in a low level mosaicism. A parental transmission of the triplication could not be excluded since parental blood samples were not available [9]. However, this has been excluded in our patient because her parents' karyotypes were normal.

Mechanisms for the formation of the intrachromosomal triplication include; i) fusion of the inverted duplicated supernumerary marker chromosome with the normal homologue; ii) unequal crossover or interhomologue translocation followed by the inverted insertion at the former breakpoint junction; iii) two U-type exchanges among three chromatids [14-16]. Powis et al. [9] speculated that triplication of chromosome 12p could have arisen from telomere to telomere fusion of supernumerary analphoid isochromosome 12p with a normal chromosome 12. Indeed, there are three reports about PKS patients with analphoid inverted duplicated supernumerary marker chromosomes consisting of chromosome 12p [4,17-18].

The clinical findings of the patient reported by Powis et al. [9] included hypotonia, brachycephaly with upslanting palpebral fissures, thin upper lip, low nasal bridge, high arched palate, a single transverse palmar crease on each hand and abnormal hair pattern. The clinical differences between this case and our case could result from differences in the degree of mosaicism and in the distribution of abnormal cells in different tissues.

As a result, we report here the third patient with intrachromosomal triplication of the short arm of chromosome 12. We conclude that intrachromosomal triplication might be a new mechanism of formation for PKS.

## ACKNOWLEDGMENTS

This study was supported by Akdeniz University Scientific Projects Management Unit, Akdeniz University, Antalya, Turkey.

## REFERENCES

1. Pallister PD, Meisner LF, Elejalde BR, Francke U, Hermann J, Spranger J, Tiddy W, Inhorn SL, Opitz JM. The pallister mosaic syndrome. *Birth Defects Orig Article Ser.* 1977; 13(3B): 103-110.
2. Teschler-Nicola M, Killian W. Case report 72: mental retardation, unusual facial appearance, abnormal hair. *Synd Ident.* 1981; 7(1): 6-7.
3. Mowery-Rushton PA, Stadler MP, Kochmar SJ, McPherson E, Surti U, Hogge WA. The use of interphase FISH for prenatal diagnosis of Pallister-Killian syndrome. *Prenat Diagn.* 1997; 17(3): 255-265.
4. Vermeesch JR, Melotte C, Salden I, Riegel M, Trifonov V, Polityko A, Rumyantseva N, Naumchik I, Starke H, Mattheijs G, Schinzel A, Fryns JP, Liehr T. Tetrasomy 12pter-12p13.31 in a girl with partial Pallister-Killian syndrome phenotype. *Eur J Med Genet.* 2005; 48(3): 319-327.
5. Yeung A, Francis D, Giouzeppos O, Amor DJ. Pallister-Killian syndrome caused by mosaicism for a supernumerary ring chromosome 12p. *Am J Med Genet A.* 2009; 149A(3): 505-509.
6. Schinzel AA. Tetrasomy 12p (Pallister-Killian syndrome). *J Med Genet.* 1991; 28(2): 122-125.
7. Liehr T, Wegner RD, Stumm M, Joksić G, Polityko A, Kosyakova N, Ewers E, Reich D, Wagner R, Weise A. Pallister-Killian syndrome: rare phenotypic features and variable karyotypes. *Balkan J Med Genet.* 2008; 11(2): 65-68.
8. Eckel H, Wimmer R, Volleth M, Jakubiczka S, Muschke P, Wieacker P. Intrachromosomal triplication 12p11.22-p12.3 and gonadal mosaicism of partial tetrasomy 12p. *Am J Med Genet A.* 2006; 140(11): 1219-1222.
9. Powis Z, Kang SH, Cooper ML, Patel A, Peiffer DA, Hawkins A, Heidenreich R, Gunderson KL, Cheung SW, Erickson RP. Mosaic tetrasomy 12p with triplication of 12p detected by array-based comparative genomic hybridization of peripheral blood DNA. *Am J Med Genet A.* 2007; 143A(24): 2910-2915.
10. Benn PA, Perle MA. Chromosome staining and banding techniques. In: Rooney DE, Czepulkowski BH, Eds. *Human Cytogenetics: A Practical Approach, Vol. I. Constitutional Analysis.* Oxford: IRL Press Ltd. 1992: 91-118.
11. Liehr T. Fluorescence in situ hybridization (FISH) application guide. In: Rautenstrauss B, Liehr T, Eds. *FISH Technology.* Springer Lab Manual. Berlin: Springer. 2009: 29-30.
12. Shaffer LG, Slovak ML, Campbell LJ. *ISCN 2009: An International System for Human Cytogenetic Nomenclature (2009): Recommendations of the International Standing Committee on Human Cytogenetic Nomenclature.* Basel: Karger Publishers, 2009.
13. Vialard F, Mignon-Ravix C, Parain D, Depetris D, Portnoi MF, Moiriot H, Mattei MG. Mechanism of intrachromosomal triplications 15q11-q13: a new clinical report. *Am J Med Genet A.* 2003; 118A(3): 229-234.
14. Schinzel AA, Brecevic L, Bernasconi F, Binkert F, Berthet F, Wuilloud A, Robinson WP. Intrachromosomal triplication of 15q11-q13. *J Med Genet.* 1994; 31(10):798-803.
15. Rivera H, Bobadilla L, Rolon A, Kunz J, Crolla JA. Intrachromosomal triplication of distal 7p. *J Med Genet.* 1998; 35(1): 78-80.
16. Wang J, Reddy KS, Wang E, Halderman L, Morgan BL, Lachman RS, Lin HJ, Cornford ME. Intrachromosomal triplication of 2q11.2-q21 in a severely malformed infant: case report and review of triplications and their possible mechanism. *Am J Med Genet.* 1999; 82(4): 312-317.
17. Dufke A, Walczak C, Liehr T, Starke H, Trifonov V, Rubtsov N, Schöning M, Enders H, Eggermann T. Partial tetrasomy 12pter-12p12.3 in a girl with Pallister-Killian syndrome: extraordinary finding of an analphoid, inverted duplicated marker. *Eur J Hum Genet.* 2001; 9(8): 572-576.
18. Huang XL, Isabel de Michelena M, Leon E, Maher TA, McClure R, Milunsky A. Pallister-Killian syndrome: tetrasomy of 12pter@12p11.22 in a boy with an analphoid, inverted duplicated marker chromosome. *Clin Genet.* 2007; 72(5): 434-440.

## INFORMATION FOR AUTHORS

### 1. Aims and scope of the journal

Balkan Journal of Medical Genetics (BJMG) was founded in 1998, and encompasses all aspects of human genetics: cytogenetics, molecular genetics, clinical genetics, immunogenetics, oncogenetics, pharmacogenetics, population genetics, genetic screening and diagnosis of monogenic and polygenic diseases, prenatal and preimplantation genetic diagnosis, genetic counseling, advances in treatment and prevention.

The journal is supported by an international Editorial Board.

The BJMG welcomes the submission of manuscripts that meet the general criteria of significance and scientific excellence, and will publish original articles, case studies, reviews, surveys, opinions, commentaries and essays.

### 2. Identification Statement

BJMG is published on the web as articles become available. The journal is published twice a year in June and November by the Macedonian Academy of Sciences and Arts.

### 3. Subscription

**Print subscription price:** 120 US\$ for public institutions and 50 US\$ for individuals.

**Reprints:** The price for 50 reprints is 50 US\$ and 100 US\$ for 100 reprints.

Payments can be made by cheque and bank transfer to the following bank account:

**Bank Name and Address:** City Bank New York, 111 Wall Street, New York, NY 10043

**Bank Account Number:** (NBRM MK 2X) 36086854

**Bank Account Owner:** National Bank of the Republic of Macedonia; Macedonian Academy of Sciences and Arts; ICGIB, Skopje

**Swift Code:** CITI USD 33

The transfer costs (taxes and commissions) are at the expense of the receiving bank and are included in the above mentioned price. Please send copy of the bank certificate to confirm the payment.

### 4. Submission of manuscripts:

Manuscripts written in English should be submitted online on [www.bjmg.edu.mk](http://www.bjmg.edu.mk) or sent by e-mail as an attached file to the Editorial Office:

*Dijana Plaseska-Karanfilska (Editor)*

*Macedonian Academy of Sciences and Arts,*

*Av. Krste Misirkov 2, POB 428*

*1000 Skopje, Republic of Macedonia*

*E-mail: manu.icgib@gmail.com*

The text files should be prepared using MS Word or Rich Text Format (RTF) and should be clearly labeled with the first author's name. Each manuscript must be accompanied by a statement that it has not been published or submitted for publication elsewhere. Authors are responsible for obtaining permission to reproduce copyrighted material from other sources and are required to sign an agreement for the transfer of copyright to the publisher. All accepted manuscripts, artwork, and photographs become the property of the publisher.

### 5. Manuscript Review

Manuscripts are evaluated by two or more expert reviewers. Authors are encouraged to suggest the names and contacts (including e-mail address) of prospective reviewers. Authors are notified of the disposition of a manuscript six weeks after receipt.

### 6. Preparation of manuscript

- All new manuscripts must be accompanied by a cover letter from the corresponding author stating that the manuscript represents original, unpublished material not under editorial consideration elsewhere, and that ethical guidelines were followed in the conduct of the research.
- All manuscripts must be written in English (the Vancouver style) and the text typed double spaced on one side of the paper only with wide margins of at least 2.5 cm on all four sides. Uniform requirements for manuscripts may be found in *Br Med J* 1991; 302:338-341, and *N Engl J Med* 1991; 324: 424-428.

## INFORMATION FOR AUTHORS

---

- The title page should contain: title of article, abbreviated running title of no more than 30 characters, author's name, department, institution, city and country, name and full postal address, telephone, fax and e-mail of the corresponding author. All pages including the title page should be numbered.
- The abstract of no more than 250 words should start on page 2. A list of 3-6 key words or short phrases should be given in alphabetic order below the abstract.
- The main text should be arranged in the following components: introduction, materials and methods, results, discussion, acknowledgments, references, figure legends and tables.
- Cite each reference, figure and table in numerical order - ex.[1-5]; (Table 1); (Fig.1).
- References (not exceeding 30-40 in number) should be numbered in order in which they are first mentioned in the text. The surnames of all authors followed by initials should be given. Abbreviate journal names in accordance with the Index Medicus system (Br Med J 1988;296:401-405).  
*Examples:* Du Manoir S, Speicher M, Joos S, Schroc E, Popp S, Dohner H, Kovacs G, Robert-Nicaud M, Lichter P, Cremer T; Detection of complete and partial chromosome gain and losses by comparative genomic in situ hybridization. Hum Genet 1993; 90:590-610.
- Place all the tables at the end of your file. Start each table on new page, complete with title and footnotes (if any). Number the tables (Arabic numerals) in the order in which they are cited in the text. Always separate the individual columns using tabulators, not using the space bar.
- Figures should be prepared on separate pages. Number the figures in Arabic numerals in the order in which they are cited in the text.