

## DE NOVO *TINF2* C.845G>A: PATHOGENIC VARIANT IN PATIENT WITH DYSKERATOSIS CONGENITA

Kocheva SA<sup>\*1</sup>, Gjorgjievska M<sup>2</sup>, Martinova K<sup>1</sup>, Antevska-Trajkova Z<sup>1</sup>, Jovanovska A<sup>1</sup>, Plaseska-Karanfilska D<sup>2</sup>

**\*Corresponding Author:** Svetlana Kocheva, MD, PhD, Department of Hematology and Oncology Children's Diseases, Majka Tereza 17, Skopje, North Macedonia, tel. +38971378184  
e-mail: dr.kocheva@gmail.com

### ABSTRACT

Dyskeratosis congenita (DC) is a clinically and genetically heterogeneous, multisystem inherited syndrome with a very high risk for bone marrow failure (BMF) and cancer predisposition. The classical clinical form of DC is characterized by abnormal skin pigmentation, nail dystrophy, and oral leukoplakia. Bone marrow failure is considered to be an important and major complication of DC and the leading cause of death which develops in around 85% of cases. A number of genes involved in [telomere maintenance](#) are associated with DC, such as genes that encode the components of the telomerase complex (*TERT*, *DKC1*, *TERC*, *NOP10*, and *NHP2*), T-loop assembly protein (*RTEL1*), telomere capping (*CTC1*), telomere shelterin complex (*TINF2*), and telomerase trafficking protein (*TCAB1*). Mutations in *TINF2* have been reported in 11–20% of all patients with DC and have been associated with bone marrow failure. Here we report on a 19-month old boy with very early presentation of bone marrow failure as a first clinical manifestation of DC. Upon first admission, the patient presented with thrombocytopenia and macrocytic anemia. Soon after, his blood counts deteriorated with the development of pancytopenia and aplastic anemia. Four months later, he developed nail dystrophy and skin hyperpigmentation. A *de novo* heterozygous pathogenic variant c.845G>A, p.(Arg282His) was located in exon 6 of *TINF2* gene and was identified via clinical exome sequencing. The findings confirmed

the diagnosis of DC. This is the first case with DC due to *TINF2* pathogenic variant reported in North Macedonia.

### Keywords

*TINF2* gene mutation; Aplastic anemia; DC

### INTRODUCTION

Dyskeratosis congenita (DC) is a clinically and genetically heterogeneous multisystem inherited syndrome caused by mutations in genes that encode the protein components of the telomerase complex and shelterin complex. DC is a rare disease with an estimated annual incidence of 1 in 1,000,000 [1]. Genotype–phenotype correlations are complex due to a variety of gene mutations, disease anticipation, and genetic and environmental modifier effects. The classical clinical form of the disease is characterized by the mucocutaneous triad of abnormal skin pigmentation, nail dystrophy, and leukoplakia [2, 3]. The abnormal skin pigmentation and nail changes usually appear first, often under 10 years of age. Additional features of the clinical presentation include BMF, myelodysplastic syndrome (MDS), epiphora, blepharitis, premature graying, alopecia, growth retardation, cerebellar hypoplasia and microcephaly, esophageal stenosis, urethral stenosis, liver disease, pulmonary fibrosis, and avascular necrosis of the hips or shoulders. DC patients have an increased risk of developing malignant disease [4, 5]. Bone marrow failure is considered to be an important and major complication of DC, and is a leading cause of death that develops in around 85% of cases. DC is caused by mutations in genes that encode protein components of the telomerase complex and shelterin complex. Since 1998 at least 14 DC genes involved in the telomere's shortening have been identified, accounting for approximately 70–80% of DC cases [6–8]. These genes encode proteins for the

<sup>1</sup> Pediatric Clinic for Children's Diseases, Ss. Cyril and Methodius University in Skopje, Faculty of Medicine, Skopje, North Macedonia

<sup>2</sup> Research Centre for Genetic Engineering and Biotechnology "Georgi D. Efremov", Macedonian Academy of Sciences and Arts, Skopje, North Macedonia

maintenance of telomeres, which are located at the ends of chromosomes. DC can be inherited in an X-linked, autosomal dominant (AD), or autosomal recessive (AR) pattern. Mutations in *TINF2* have been reported in 11–20% of all patients with DC and have been associated with bone marrow failure [9]. In addition, mutations of *TINF2* were also identified in patients with other diseases associated with bone marrow failure (e.g. ataxia-pancytopenia and aplastic anemia) [10, 11]. In this paper we report on a 19-month old boy with *de novo* heterozygous mutation in the *TINF2* gene and a very early presentation of bone marrow failure as a first clinical manifestation of DC.

## CASE PRESENTATION

A 19-month-old boy was referred to the hematology department at the University clinic for children's diseases in order to evaluate the possibility of thrombocytopenia. He is of Albanian ancestry, born after a normal pregnancy from healthy parents. There is no consanguinity in the family. Clinical examination at admission revealed pallor, cutaneous and mucosal hemorrhagic syndrome. He had growth retardation below the third percentile on the growth curve. Laboratory tests have shown thrombocytopenia (with PLT  $27 \times 10^9/l$ ), with macrocytic anemia (Hb: 102 g/L, RBC  $3.3 \times 10^9/l$ , MCV: 98.2 fL) and WBC:  $6.03 \times 10^9/l$ , neutrophil count of  $1.25 \times 10^9/l$ . BM analysis showed megaloblastic maturation in BM with megakaryocyte hypoplasia. Chromosome analysis indicated no numerical or structural chromosomal abnormalities. The following month, the PLT number decreased to  $7 \times 10^9/l$  with the development of severe macrocytic anemia (Hb 72g/L; RBC  $2.3 \times 10^9/l$ ). Blood

counts deteriorated with the development of pancytopenia and aplastic anemia. Four months later, a physical examination revealed nail dystrophy and skin pigmentation involving the neck. Differential diagnosis suggested Fancony anemia or DC. The diagnosis of DC was established with the identification of a known pathogenic *de novo* *TINF2* gene mutation. The clinical characteristic and hematology findings during the follow up are summarized in Table 1.

## GENETIC ANALYSIS AND RESULTS

We performed clinical exome sequencing on a MiSeq desktop sequencer, using TruSight One kit (Illumina) for the proband. The analysis revealed the presence of the known pathogenic variant c.845G>A, p.(Arg282His), in a heterozygous state, in the *TINF2* gene (Figure 1). Amplification and Sanger sequencing of *TINF2* exon 6 showed the absence of the variant in the proband's parents. DNA analysis using the AmpFLSTR Identifiler PCR Amplification Kit confirmed the biological relationship between the child and his parents. Thus, the *TINF2* c.845G>A variant has arisen as a *de novo* event in the proband. Schematic representation of the pathogenic *TINF2* gene variants is presented in Figure 2.




Figure 1. *TINF2* gene exon 6 direct sequencing results in the proband.

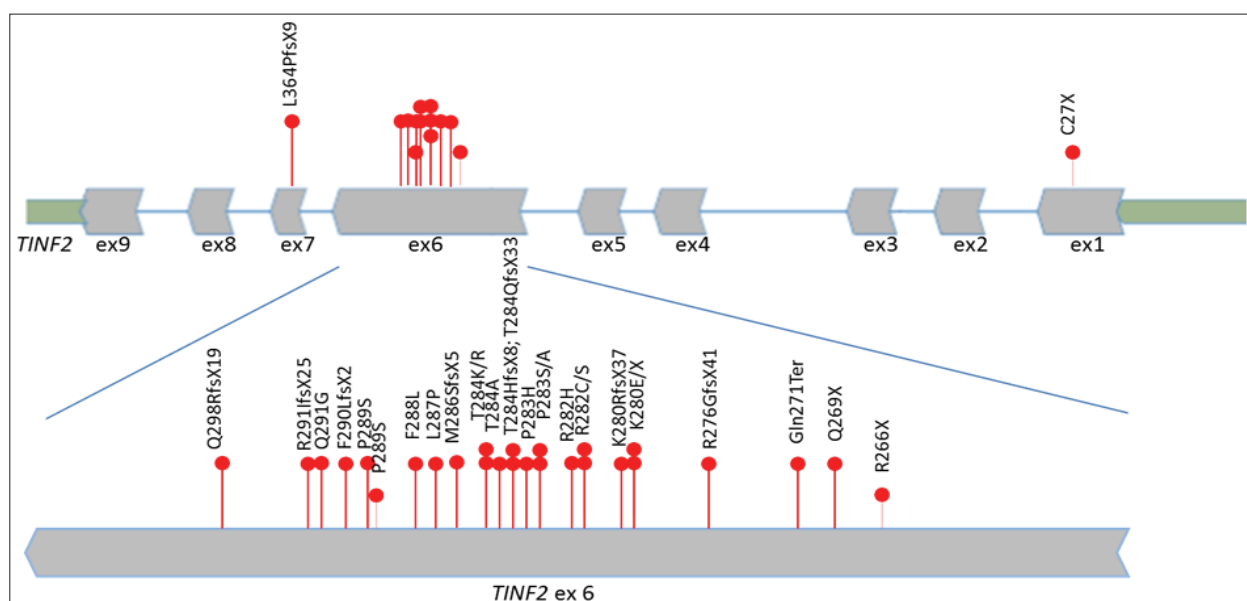


Figure 2. Schematic representation of the pathogenic *TINF2* gene variants.

**Table 1.** Hematology results and clinical characteristic during the follow up

Analysis	1 st admission	2 months	4 months
Hb (g/l)	102	86	72
RBC (10 <sup>9</sup> /l)	3.3	2.6	2.3
MCV (fl)	98.2	102	105
WBC (10 <sup>9</sup> /l)	6.03	4.8	4.9
Granulocyte (10 <sup>9</sup> /l)	1.25	1.0	0.8
PLT (10 <sup>9</sup> /l)	27	12	7
BM aspiration and BM biopsy	Megaloblastic maturation, Megakaryocytic hypoplasia		Hypo plastic, fatty bone marrow
Nail dystrophy	No	No	Present
Skin hyperpigmentation	No	No	Present
Mucosal Leucoplakia	No	No	No
Genetic analyses			c.845G>A, p.(Arg282His)

## TREATMENT

The medical management of each DC patient is very complex and should take into consideration the patient's specific needs. Patients with DC and BMF do not respond to immunosuppressive therapy, and allogeneic hematopoietic stem cell transplantation (HSCT) is the only curative treatment for BMF. Our patient received corticosteroids for one month without any response to the therapy. After the confirmation of DC, HSCT was performed by an unrelated full matched donor. The patient experienced engraftment failure and underwent a second unrelated HSCT. One year after the second HSCT he was in a good clinical condition. Once the bone marrow failure issue was resolved, thrombocytes were around 30-40 x 10<sup>9</sup>/l and the boy had a relatively good quality of life.

## DISCUSSION

We report the clinical, laboratory and genetic findings of a 19-month-old Albanian boy from North Macedonia with aplastic anemia as a first clinical presentation of DC. A known pathogenic missense variant, c.845G>A, p.(Arg282His), located in exon 6 of the *TINF2* gene, was identified as responsible for DC in our patient.

Autosomal dominant DC is a clinically and genetically heterogeneous group of the disease. To date, heterozygous variants in 4 genes (*TERC*, *TERT*, *RTEL1* and *TINF2*) have been characterized. Patients harboring *TINF2* variants are reported to have extremely short telomeres, and a frequent early age of presentation (less than 10 years old), and they often present severe manifestation of the disease [8, 14]. Nearly all patients have *de novo* *TINF2* variants that give

rise to a different mechanism that causes the disease. List of the known *TINF2* pathogenic variants reported to date is given in Table 2. *TINF2* mutations can be associated with a broad spectrum of phenotypes (Table 2, on the next page). The classical clinical form of the disease is characterized by dysplastic nails, lacy reticular pigmentation of the upper chest and/or neck and oral leukoplakia. BMF, myelodysplastic syndrome (MDS), epiphora, blepharitis, premature graying, alopecia, growth retardation, cerebellar hypoplasia and microcephaly, esophageal stenosis, urethral stenosis, liver disease, pulmonary fibrosis, and avascular necrosis of the hips or shoulders can be included in the clinical presentation. Progressive bone marrow failure may appear at any age and may be the only sign until the age of 10. Macrocytosis and elevated hemoglobin F levels may be seen in these patients. Patients have an increased risk of the development of malignant disease. Solid tumors may be the first manifestation of DC in persons who do not have BMF and are younger than 50 years of age [15]. Most DC patients have normal intelligence and development of motor skills. In severe forms of the disease, developmental delay may occur. In Hoyeraal Hreidarsson syndrome, a severe form of the disease, affected individuals have an unusually small and underdeveloped cerebellum and intrauterine growth retardation. In addition to the other symptoms of dyskeratosis congenita, bilateral exudative retinopathy and intracranial calcifications are characteristic for the other severe variant of DC, called Revesz syndrome [16]. Pulmonary fibrosis was found in DC patients with the c.844C>T p.(Arg282Cys), c.851C>G p.(Thr284Arg) and c.872\_875del p.(Arg291IlefsTer25) *TINF2* pathogenic variants [14, 17, 18].

The *TINF2* pathogenic variant c.845G>A, p.Arg282His that was identified in our patient has been previously reported in patients with severe clinical presentations, such as Hoyeraal Hreidarsson syndrome and Revesz syndrome (8, 11).

## CONCLUSION

DC is a rare genetic disorder with genetic and clinical heterogeneity. Patients with aplastic anemia should be screened for this rare condition, even when they do not have a classical clinical form. Reporting different cases increases our knowledge of the disease and its heterogeneity. Early diagnosis allows for prevention of severe invasive infections and non-infectious complications, thus improving the success of transplantation and overall prognosis of DC.

**Declaration of Interest.** The authors report no conflicts of interest. The authors alone are responsible for the content and writing of this article.

**Table 2.** List of known pathogenic *TINF2* gene variants

Chr Position (GRCh37)	Nucleotide change (NM_001099274)	Amino acid change (NP_001092744)	rs ID	Phenotype	Publication (Reference)
chr14:24711458	c.81C>A	p.Cys27Ter	rs1060499576	DC, RS	/
chr14:24709890	c.796C>T	p.Arg266Ter	rs1064795632	N/A	/
chr14:24709881	c.805C>T	p.Gln269Ter	rs387907153	DC, mucocutaneous features, BMF	19, 18
chr14:24709875	c.811C>T	p.Gln271Ter	rs387907154	AA	19
chr14:24709860	c.826delA	p.Arg276GlyfsTer41	rs863223324	ND, BMF, lichenoid tongue, dry skin, intrauterine growth retardation	18
chr14:24709848	c.838A>T	p.Lys280Ter	rs121918543	DC, HHS, and RS	12, 15
chr14:24709848	c.838A>G	p.Lys280Glu	rs121918543	DC	12, 21, 8
chr14:24709847	c.839delA	p.Lys280ArgfsTer37	rs1594551449	DC, RS	19
chr14:24709842	c.844C>A	p.Arg282Ser	rs121918545	DC, RS	12, 17, 23
chr14:24709842	c.844C>T	p.Arg282Cys	rs121918545	DC, AA, PD and mucosal changes	20, 12, 17
chr14:24709841	c.845G>A	p.Arg282His	rs121918544	DC, HHS, RS	12, 22, 17, 24, 25, 26, 27, 28
chr14:24709839	c.847C>T	p.Pro283Ser	rs199422311	DC, HHS	12, 15
chr14:24709839	c.847C>G	p.Pro283Ala	rs199422311	DC	12, 15
chr14:24709838	c.848C>A	p.Pro283His	rs199422313	DC	12, 15
chr14:24709837	c.849delC	p.Thr284GlnfsTer33	/	ND, BMF	18
chr14:24709837	c.849_850insC	p.Thr284HisfsTer8	rs199422315	DC, AA	12, 15
chr14:24709836	c.850A>G	p.Thr284Ala	rs199422314	DC	12, 15
chr14:24709835	c.851C>A	p.Thr284Lys	/	DC	18
chr14:24709835	c.851C>G	p.Thr284Arg	/	BMF, hair loss, dental loss, PD, short stature, osteoporosis	18
chr14:24709829	c.857delTinsGC	p.Met286SerfsTer5	/	ND, BMF, microcephaly, low immunoglobulins	18
chr14:24709826	c.860T>C	p.Leu287Pro	rs199422316	DC	12, 15
chr14:24709824	c.862T>C	p.Phe288Leu	rs199422317	DC	12, 15
chr14:24709821	c.865C>T	p.Pro289Ser	rs1555304055	N/A	29
chr14:24709820	c.865_866delinsAG	p.Pro289Ser	rs199422318	DC	12, 15
chr14:24709819	c.867_868insC	p.Phe290LeufsTer2	/	DC	12
chr14:24709815	c.871A>G	p.Arg291Gly	rs199422319	DC	12, 15
chr14:24709812	c.872_875del	p.Arg291IlefsTer25	/	DC, PD	14
chr14:24709794	c.892delC	p.Gln298ArgfsTer19	rs199422320	DC	12, 15
chr14:24709508	c.1090dup	p.Leu364ProfsTer9	rs1566366182	DC	/

DC - Dyskeratosis congenita, HHS - Hoyeraal Hreidarsson syndrome, RS - Revesz syndrome, BMF - Bone marrow failure, AA - Aplastic anemia, PD - Pulmonary disease, ND - Nail dystrophy

## REFERENCES

- Walne AJ, Marrone A, Dokal I: Dyskeratosis congenita: a disorder of defective telomere maintenance? *Int J Hematol* 2005; 82:184–189.
- Dokal I. Dyskeratosis congenita in all its forms. *Br J Haematol*. 2000; 110: 768-779.
- Bessler M, Wilson DB, Mason PJ. Dyskeratosis congenita. *FEBS Lett*. 2010; 584: 3831-3838.
- Ballew BJ, Savage SA. Updates on the biology and management of dyskeratosis congenita and related telomere biology disorders. *Expert Rev Hematol*. 2013; 6: 327–37.
- Alter BP, Giri N, Savage SA, Rosenberg PS. Cancer in dyskeratosis congenita. *Blood*. 2009; 113(26): 6549-57.
- Heiss NS, Knight SW, Vulliamy T, SM Klauck, S Wiemann, P J Mason et al. X-linked dyskeratosis congenita is caused by mutations in a highly conserved



- gene with putative nucleolar functions. *Nat Genet.* 1998; 19: 32-38.
7. Walne AJ, Dokal I: Advances in the understanding of dyskeratosis congenita. *Br J Haematol.* 2009; 145: 164-172.
  8. Savage SA, Giri N, Baerlocher GM, Orr N, Lansdorp PM, Alter BP: TINF2, a component of the shelterin telomere protection complex, is mutated in dyskeratosis congenita. *Am J Hum Genet.* 2008; 82: 501-509.
  9. Calado RT (ed): *Progress in Molecular Biology and Translational Science*, ed 1. Waltham, Academic Press, 2014.
  10. Du HY, Mason PJ, Bessler M, and Wilson DB. *Pediatr. Blood Cancer.* 2009; 52: 687.
  11. Tsangaris E, Adams SL, Yoon G, Chitayat D, Lansdorp P, Dokal I, and Dror Y. *Hum. Genet.* 2008; 124: 507-513.
  12. Walne AJ, Vulliamy T, Beswick R, Michael K, Dokal I. TINF2 mutations result in very short telomeres: analysis of a large cohort of patients with dyskeratosis congenita and related bone marrow failure syndromes. *Blood.* 2008; 112(9): 3594–3600.
  13. Sarper N, Zengin E, Kilic SC. A child with severe form of dyskeratosis congenita and TINF2 mutation of shelterin complex. *Pediatr Blood Cancer.* 2010; 55(6):1185–1186.
  14. Fukuhara A, Tanino Y, Ishii T, Inokoshi Y, Saito K, Fukuhara N et al. Pulmonary fibrosis in dyskeratosis congenita with TINF2 gene mutation. *Eur Respir J.* 2013; 42: 1757–1759.
  15. Savage SA. Dyskeratosis Congenita. 2009 Nov 12 [updated 2019 Nov 21]. In: Adam MP, Ardinger HH, Pagon RA, Wallace SE, Bean LJH, Mirzaa G, Amemiya A, editors. *GeneReviews®* [Internet]. Seattle (WA): University of Washington, Seattle; 1993-2021. Available from <http://www.ncbi.nlm.nih.gov/books/NBK22301/> Citation on PubMed
  16. Karremann M, Neumaier-Probst E, Schlichtenbrede F, Beier F, Brümmendorf TH, et al. Revesz syndrome revisited. *Orphanet J Rare Dis.* 2020; 15: 299.
  17. Hongchun D, Yubiao G, Di M, Kejing T, Decheng C, et al. A case report of heterozygous TINF2 gene mutation associated with pulmonary fibrosis in a patient with dyskeratosis congenita. *Medicine (Baltimore).* 2018; 97(19): e0724.
  18. Vulliamy T, Beswick R, Kirwan MJ, Hossain U, Walne AJ, and Dokal I. Telomere length measurement can distinguish pathogenic from non-pathogenic variants in the shelterin component, TINF2. *Clin Genet.* 2012; 81(1): 76-81.
  19. Sasa GS, Ribes-Zamora A. Nelson ND, Bertuch AA. Three novel truncating TINF2 mutations causing severe dyskeratosis congenita in early childhood. *Clin Genet.* 2012; 81(5): 470-8.
  20. Gutierrez-Rodriguez F, Donaires FS, Pinto A, Vicente A, Dillon LW et al. Pathogenic TERT promoter variants in telomere diseases. *Genet Med.* 2019; 21(7): 1594-1602.
  21. Yang D, He Q, Kim H, Ma W, Songyang Z. TIN2 protein dyskeratosis congenita missense mutants are defective in association with telomerase. *J Biol Chem.* 2011; 286 (26): 23022-30.
  22. Li F, Li W, Qiao X, Xie X. Clinical features of dyskeratosis congenita in mainland China: case reports and literature review. *Int J Hematol.* 2019; 109(3): 328-335.
  23. Pereboeva L, Hubbard M, Goldman FD, Westin ER. Robust DNA Damage Response and Elevated Reactive Oxygen Species in TINF2-Mutated Dyskeratosis Congenita Cells. *PLoS One.* 2016; 11(2): e0148793.
  24. Nelson ND, Dodson LM, Escudero L, Sukumar AT, Williams CL, Mihalek I, et al. The C-Terminal Extension Unique to the Long Isoform of the Shelterin Component TIN2 Enhances Its Interaction with TRF2 in a Phosphorylation and Dyskeratosis Congenita Cluster-Dependent Fashion. *Mol Cell Biol.* 2018; 38(12): e00025-18.
  25. Norberg A, Rosén A, Raaschou-Jensen K, Kjeldsen L, Moilanen JS, Paulsson-Karlsson Y, et al. Novel variants in Nordic patients referred for genetic testing of telomere-related disorders. *Eur J Hum Genet.* 2018; 26(6): 858-867.
  26. Moussa K, Huang JN, Moore AT. Revesz syndrome masquerading as traumatic retinal detachment. *J AAPOS.* 2017; 21(5): 422-425.
  27. Monoi A, Sugawa M, Kato M, Seki M, Yoshida K, Shiraishi Y, et al. Atypical dyskeratosis congenita diagnosed using whole-exome sequencing. *Pediatr Int.* 2017; 59(8): 933-935.
  28. Guidugli L, Johnson AK, Alkorta-Aranburu G, Nelakuditi V, Arndt K, Churpek JE, L at all. A Godley, D Townsley, N S Young, C Fitzpatrick, D Del Gaudio, S Das 1, Z Li 1. Clinical utility of gene panel-based testing for hereditary myelodysplastic syndrome/acute leukemia predisposition syndromes. *Leukemia.* 2017; 31(5): 1226-1229.
  29. Tomcikova D, Gerinec A, Busanyova B, Gresikova M, Biskup S, Kortnagel K. Why is it necessary to examine retina when the patient suffers from aplastic anemia? *Bratisl Lek Listy.* 2018;119(5): 275-277.

